

## Sialolipoma of parotid gland, a rare benign tumor

Ranjan R<sup>1</sup>, Jha RK<sup>2</sup>, Malua S<sup>3</sup>, Bodra P<sup>4</sup>, Murari K<sup>5</sup>

<sup>1</sup>Dr Ravi Ranjan  
Junior Resident  
dr.raviranjanpandey@gmail.com

<sup>2</sup>Dr Rohit kumar jha  
Senior Resident  
withrohitjha@gmail.com

<sup>3</sup>Dr Shital Malua  
Associate Professor  
shitalmalua@gmail.com

<sup>4</sup>Dr Pankaj Bodra  
Associate Professor  
pankajbodra@gmail.com

<sup>5</sup>Dr Krishna Murari  
Assistant Professor  
drkmurari@gmail.com

<sup>1,2,3,4,5</sup>Dept. of Surgery  
Rajendra Institute of Medical  
Sciences  
Ranchi, India

Received: 16-02-2015

Revised: 10-03-2015

Accepted: 20-04-2015

Correspondence to:

Dr Ravi Ranjan  
dr.raviranjanpandey@gmail.com

### ABSTRACT

Sialolipoma is a rare tumour found within both major and minor salivary glands. A total of 35 sialolipoma cases have been reported 18 within major salivary gland and 17 within minor salivary gland. Major gland sialolipoma most often are presented in the parotid gland (77%) and those from minor salivary glands were often seen in the palate (41%). All lesions were well circumscribed and contained mature adipose tissue admixed with benign salivary gland component. Treatment is surgical excision.

We report a case of 52 years old male who presented with the complaint of swelling in the left parotid region for 22 years duration. Apart from cosmetic reason he has no other complain. All specific investigations done were inconclusive and suggested a benign tumor. Histopathological examination after superficial parotidectomy suggested sialolipoma.

**Key Words:** Major salivary gland tumour, sialolipoma, parotid gland, lipoma, benign tumor

### Introduction

Sialolipoma is a new variant of salivary gland lipoma, first reported by Nagoa et al who defined it as a well-circumscribed lesion composed by mature adipose tissue and entrapped normal salivary gland with a thin fibrous capsule.<sup>[1]</sup> Currently there are 35 cases of sialolipoma reported in literature.

The overall incidence of salivary gland tumour in adults is 0.3%. Previous studies identified no recurrence, malignant transformation or other complication following conservative surgical excision. However one exceptional case of parotid gland sialolipoma with recurrence following superficial parotidectomy has been reported in April 2014.<sup>[2]</sup> Here we report the 36<sup>th</sup> case of parotid gland sialolipoma.

### Case Report

A 52 year old male presented with a swelling in left parotid region of 22 years duration. There was no history of xerostomia, salivary pain, odynophagia, dysphagia, weight loss, mouth pain, facial weakness, haemoptysis, infection or conditions associated with immunodeficiency.

On examination a swelling of size 8.0 cm x 7.0 cm was noted in the left parotid region, extending from front of left ear to uppermost part of neck. The swelling was non tender and temperature was normal. Consistency was soft and lump was mobile.

FNAC suggested angiomatous lesion. Colour Doppler study suggested no communication with vessels. CT scan of the swelling was inconclusive and showed a hypo dense mass of varying attenuation

showing no enhancement on post contrast study. The mass measured 9.0 cm x 7.0 cm. No adjacent soft tissue involvement or bony erosion was noted. CT suggested benign parotid tumour. The patient was treated surgically with left superficial parotidectomy.

On gross pathological examination a tissue of size 9.0 cm x 5.0 cm x 2.0 cm, pinkish yellow in colour showing multiple empty spaces on one surface and other surface was smooth. Cut surface showed multiple empty spaces. Microscopic feature of the section showed diffuse extent of benign adipose tissue containing entrapped benign salivary gland tissue [fig 1]. In between the adipose tissue were noted several cystic spaces which are not lined with endothelial cells. No evidence of malignancy found. A diagnosis of sialolipoma was rendered.

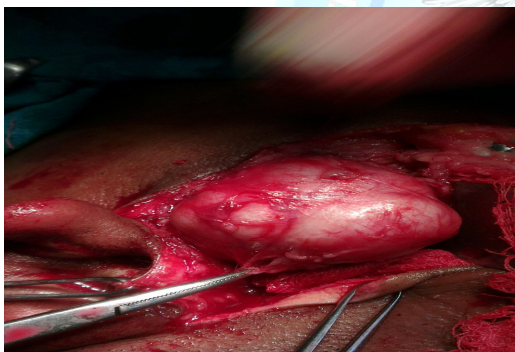


Fig. 1 Image showing sialolipoma of parotid gland

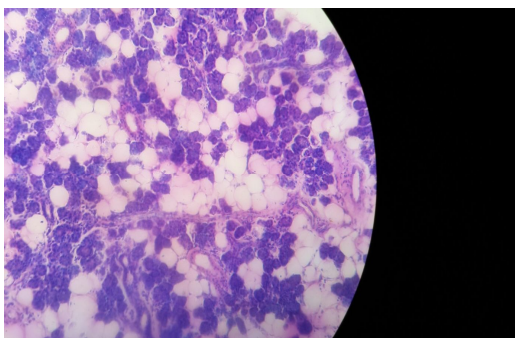


Fig. 2 Image showing adipose cells with salivary gland tissue [H & E, 100X]

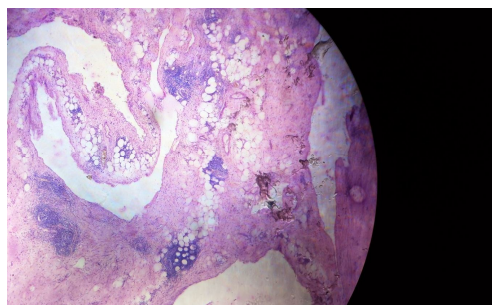


Fig. 3 Image showing glandular element with fat cells [H & E, 40X]

### Discussion

Although lipoma is a common soft tissue tumour, salivary gland lipoma is rare. Oncocytic metaplasia with mild to moderate lymphocytic infiltrate are characteristic of these lesions. Glandular atrophy, periductal fibrosis, ductal dilatation and peripheral nerve involvement are additional features reported in earlier cases but were not present in our case.

Some reports have documented that CT and/or MRI findings of sialolipoma and stated that these imaging modalities may be diagnostically useful because sialolipoma appears as well circumscribed tumour with low attenuation on CT signal and high intensity on MRI.<sup>[3, 4]</sup>

Sialolipoma is predominantly present in males, and commonly involves parotid than other minor salivary gland. The average age of presentation is 42 years, in our case the patient presented at age of 52 years. The mode of presentation was painless swelling in parotid region which was similar to other reported cases.<sup>[5]</sup> The duration of symptoms in our case was 22 years but in more than 60 percent of reported major salivary gland sialolipoma, the duration of symptom was less than 12 months.<sup>[5]</sup>

The tumor mass was encapsulated which was similar to other reported cases, but adipose tissue constituted about 50 percent of the tumor mass. In other reported cases the adipose tissue consists

of more than 75 percent of tumor mass in major salivary gland tumor. In a tabulated analysis of 36 cases (including our own),

we compared the features of sialolipoma within major and minor salivary glands.

**Table 1: Comparison of sialolipoma in major and minor salivary gland<sup>[5]</sup>**

VARIABLES	MAJOR SALIVARY GLANDS	MINOR SALIVARY GLANDS
Reported cases	18	17
Location	Parotid (77%), submandibular (23%), sublingual (0%)	Hard & soft palate (41%), Floor of mouth (18%), Buccal mucosa (18%), tongue (12%), retromolar pad & lower lip (6% each)
Age at presentation	42	62
Sex	Male (67%) female (33%)	Female (73%) male (27%)
Average size of lesion (cm)	3.2	1.98
Duration of symptoms (months)	35, 60%<12 months	55, 75%>12 months
Paediatric Sialolipoma	4 cases (newborn, 3,3,11 years)	None
Clinical symptoms	Slow growing painless swelling	Slow growing painless swelling
Treatment	Surgical Excision	Surgical Excision
Recurrence	One case in 2014 (parotid)	None
<b>HISTOLOGY FINDINGS</b>		
Encapsulated	100%	88%
Adipose tissue	75-90% tumor is mature fat	50-70% of tumor is mature fat
Atrophic glands	42%	93%
Fibrosis	21%	53%
Ductal dilatation/Ectasia	28%	100%
Ductal metaplasia (oncocytic)	35%	20%
Peripheral nerve entrapment	0%	13%
Ductal metaplasia (squamous)	14%	20%
Enlarged congested vessels	7%	26%

The typical clinical presentation was that of a painless slow-growing mass, most

commonly in parotid gland or palate. While the age distribution for major

salivary gland sialolipoma was diverse (including four paediatric cases), minor salivary gland tumours were reported in adults only. Major salivary gland lesions were larger compared with minor salivary gland lesions, likely related to more room for the lesion to grow within the larger salivary gland prior to being noticed.

Histopathological features were also compared between major and minor salivary gland sialolipoma. Most lesions in either group were well circumscribed and contained mature fat intimately admixed with benign salivary gland components. Nerve entrapment was noted only in major salivary glands whereas myxoid degeneration was observed only in minor salivary gland tumours.

Akrish et al<sup>[6]</sup> hypothesized that pathogenesis of sialolipoma may be associated with some form of salivary gland dysfunction, leading to altered salivary gland configuration. This concept is favoured microscopically by replacement of the normal salivary gland tissue with mature adipose tissue admixed with atrophic salivary glandular elements, and/or chronic ductal epithelial changes (oncocyctic metaplasia, fibrosis and lymphocytic infiltrate). Presence of similar histological findings in other conditions related to salivary gland dysfunction, for example, sialadenosis, senile and reactive salivary gland changes further supports the above argument.

The differential diagnosis of sialolipoma includes lipomatous lesions such as lipomatosis<sup>[7]</sup>, lipoadenoma<sup>[8]</sup>, and pleomorphic adenoma<sup>[8]</sup> with an extensive fat constituent. CT or magnetic resonance imaging can be helpful in narrowing the differential diagnosis and are superior to ultrasonography in defining exact location and texture of the lesion. Fine needle aspiration, which is the first line procedure in diagnosing major salivary gland lesions, is of little help, as its

accuracy is less than 50% in lipomatous tumours. Treatment of choice is surgical excision for both major and minor salivary glands sialolipomas.

### **Conclusion**

Sialolipoma is a rare benign tumor of salivary gland. Pre operative diagnosis is difficult. Excision of the tumor is the gold standard for treatment. Recurrence is rare, though one case of recurrence has been reported.

### **References**

1. Nagao T, Sugano I, Ishida Y. Sialolipoma: a report of seven cases of a new variant of salivary gland lipoma. *Histopathology* 2001;38:30–36.
2. Po-Han Lee, Jiann-JY Chen and Yung-AN Tsou. A recurrent sialolipoma of the parotid gland: A case report. *Oncol Lett* Jun 2014;7(6):1981–1983.
3. Okada H, Yokoyama M, Hara M, Akimoto Y, Kaneda T, Yamamoto H. Sialolipoma of the palate: A rare case and review of literature. *Oral Surg Oral Med Oral Pathol Oral Radiol Endod* Oct 2009;108(4):571-76.
4. Cappabianca S, Colella G, Pezzullo MG, Russo A, Oaselli F, Brunese L, et al. Lipomatous lesions of the head and neck region: Imaging findings in comparison with histological type. *Radiol Med* 2008;113:758-70.
5. Qayyum Sohail, Meacham Ryan, Sebelik Messy, Zafar Nadam. Sialolipoma of parotid gland: case report with literature review comparing major and minor salivary gland sialolipoma. *J oral maxillofac pathol* 2013;17(1):95-97.
6. Akrish S, Leiser Y, Shamira D, Peled M. Sialolipoma of the salivary gland: two new cases, literature review, and histogenetic hypothesis. *J Oral Maxillofac Surg* 2011; 69:1380–1384.

7. Saleh HA, Harmse JL, Michie BA, Blair RL. Lipomatosis of the minor salivary glands. *J Laryngol Otol* 1998;112:895-97.
8. Yau KC, Tsang WYW, Chan JKC. Lipoadenoma of the parotid gland with probable striated duct differentiation. *Mod Pathol* 1997;20:242-246.
9. Jin YT, Lian JD, Yan JJ, Hwang TZ, Tsai ST. Pleomorphic adenoma with extensive adipose content. *Histopathology* 1996;28:87-89.

**Cite this article as: Ranjan R, Jha RK, Malua S, Bodra P, Murari K. Sialolipoma of parotid gland, a rare benign tumor. *Int J Med and Dent Sci* 2015; 4(2):886-890.**

**Source of Support: Nil  
Conflict of Interest: No**

