

Posterior reversible encephalopathy syndrome: A rare entity

Khurana M¹, Mahajan D², Anand M³, Chhabra A⁴

¹Dr Maxima Khurana
Assistant Professor, Medicine
maxima.khurana@gmail.com

²Dr Devinder Mahajan
Professor, Medicine
drdevin2008@yahoo.com

³Dr Manan Anand
DNB Cardiology, Assistant Professor
manan_anand@yahoo.com

⁴Dr Ajay Chhabra
Assistant Professor
Government Medical College
Amritsar, Punjab, India
drajaychhabra@gmail.com
^{1,2,3}Shri Guru Ram Dass Institute of
Medical Sciences & Research
Amritsar, Punjab, India

Received: 30-08-2014

Revised: 01-10-2014

Accepted: 20-10-2014

Correspondence to:

Dr Maxima Khurana
maxima.khurana@gmail.com

ABSTRACT

Posterior reversible encephalopathy syndrome(PRES) is a proposed reversible cliniconeurological entity characterized by headache, altered mental status, cortical blindness, seizures, focal neurological signs and a diagnostic magnetic resonance image showing multiple hyperintense signal in cortical and subcortical white matter. We report a case of 25 year female who presented 2 days postdelivery with posterior reversible encephalopathy syndrome. Early diagnosis with MRI showing bilateral parietal and occipital hyperintensities and treatment with manitol, antiepileptics and supportive measure, the syndrome was fully reversible. Clinicians as well as radiologists should be familiar with this clinically frightening, underdiagnosed condition to assure timely diagnosis and treatment to prevent persistent neurological deficits.

Keywords: Posterior reversible encephalopathy syndrome, neurological deficit, white matter hyperintensities, postdelivery, reversible

Introduction

In 1996, Hinchey et al reported a clinic-radiological picture, they called reversible posterior leukoencephalopathy syndrome. They described 15 patients with a reversible predominantly posterior leukoencephalopathy. There has been a controversy about what should be the proper term for this syndrome. In 2000, Casey et al proposed the term posterior reversible encephalopathy syndrome (PRES).^[1]

Underlying clinical conditions predisposing to PRES include chronic renal insufficiency, toxemia of pregnancy, pediatric post-streptococcal glomerulonephritis, thrombotic thrombocytopenic purpura, haemolytic uraemic syndrome, autoimmune disorders alone or together with exposure to immunomodulating agents (cyclosporine, tacrolimus, interferon-alpha, cisplatin,

cyclophosphamide).^[2] This rare condition usually not suspected can cause permanent neurological damage if not treated. Therefore, early diagnosis and treatment is necessary.^[3]

Case Report

A 25 year old female presented to emergency department with complaints of loss of consciousness two days after a normal vaginal delivery in an outside hospital. She was gravida three and para two. Her antenatal blood pressure was reported to be normal in the last trimester. She had no complaints of headache, seizure, fever, profuse bleeding, weakness of any part or decreased urine output. Her family history for neurological and other chronic diseases was normal. On examination, her Glasgow coma scale was 5/15. Her general examination was unremarkable. On central nervous

examination, pupils were normal in size and reacting to light. Fundus examination was normal except for mild disc hyperemia. No sign of meningeal irritation were found. Motor examination showed diminished reflexes and hypotonia without any focal neurological deficit. Plantars were equivocal. Abdominal, cardiovascular and respiratory system examinations were unremarkable. On investigation, her Hb was 9.9mg/dl, WBC- 9470, Platelet count-40,000, ESR – 30. Peripheral smear showed normocytic, mildly hypochromic anaemia with few microcytes. No haemoparasite was seen. Renal function test, serum electrolytes, blood sugar, liver function test and chest x-ray were normal. Bleeding and clotting parameters were normal. Immunological markers for hepatitis B and C, HIV, CMV, HSV and dengue were negative. ECG was normal. Echo was normal. Urine routine examination revealed trace proteinuria. Parameters for vasculitis and hypercoaguable state were negative. MRI brain (Figure 1) revealed multiple cortical and subcortical hyperintense signal in both parietal lobes, occipital lobes and pons.

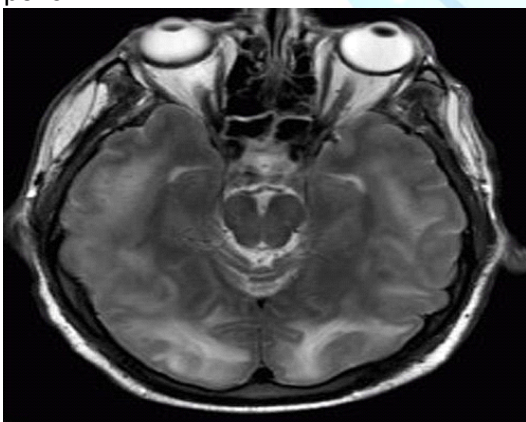


Fig. 1 Multiple hyperintense signals in parietal and occipital lobe bilaterally.

CSF examination was normal. Patient was admitted in the ICU and treated with mannitol 100 mg thrice a day, antiepileptics (phenytoin 100 mg intravenous thrice a day, strict control of blood pressure,

antibiotics (ceftriaxone 2gm intravenous twice a day) and other supportive measures. Her sensorium improved with this treatment in 7 to 9 days. She was shifted out of ICU and discharged subsequently in 1 week. Her MRI brain before discharge was normal (Figure2).

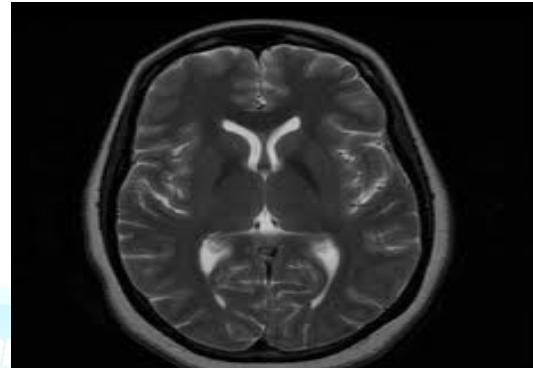


Fig. 2 Normal MRI

Discussion

This case of PRES is rare and underdiagnosed entity. Physicians and obstetricians are not very familiar with it. With early diagnosis and treatment it can be completely reversed.^[4]

Diagnostic criteria for posterior reversible encephalopathy syndrome (PRES)^[5]

1. The presence of neurological symptoms or findings such as epilepsy, weakness of an extremity, or mental status changes.
2. Presence of risk factors for PRES such as cyclosporine treatment, eclampsia, or history of hypertension (diastolic blood pressure >100 mmHg).
3. Absence of other possible causes of encephalopathy.
4. Reversible course, disappearance of signal changes on follow-up images, or complete resolution of clinical symptoms and signs following treatment.

Two possible mechanisms have been proposed in the pathophysiology. The first is vasospasm due to acutely increased blood pressure and second is loss of autoregulation. In the first hypothesis it has been suggested that vasospasm contributes

to ischemia and cytotoxic edema at regions of the arterial border zone. [6] The second, more recent hypothesis is supported by diffusion images suggesting that dilatation develops in cerebral arterioles due to autoregulatory failure. The objective of autoregulation is to keep blood flow constant and to protect the brain during pressure changes; however sudden and severe increase in blood pressure can impair autoregulation, and such impairment can, in turn, lead to arteriolar vasodilation and endothelial dysfunction. In this condition, plasma and red blood cells migrate to the extravascular space from the intravascular space and vasogenic edema occurs. [7]

In our case, initial differential diagnosis of cortical vein thrombosis, meningoencephalitis and PRES were kept. MRI revealed high signal-intensity lesions on FLAIR (fluid attenuated inversion recovery) images, predominantly localized in (but not limited to) the subcortical white matter of bilateral occipital and parietal lobes. CSF examination being normal ruled out meningoencephalitis. MRI findings ruled out cortical vein thrombosis due to nonvisualization of clot.

In this report, early diagnosis and control of blood pressure lead to positive outcome. Thus, patients should be warned of preeclampsia symptoms, not only in the antenatal period but also in the postpartum period so that this condition can be recognized early.

Conclusion

We have presented the case of young female with PRES. Awareness of the diverse clinical and radiographic presentation of acute PRES is essential to avoid misdiagnosis and treatment delay. It is imperative that the syndrome of PRES is correctly recognized on neuro-imaging, as the condition is reversible and potential

complications can be avoided with appropriate therapy. Since PRES is often unsuspected by clinicians, recognition of the characteristic imaging findings by radiologists is key to diagnosing this syndrome and should prevent deleterious work-ups or therapies.

References

1. Hinchey J, Chaves C, Appignani B, Breen J, Pao L, Wang A, et al. A reversible posterior leukoencephalopathy syndrome. *N Engl J Med* 1996;334:494-500.
2. Kwon S, Koo J, Lee S. Clinical spectrum of reversible posterior leukoencephalopathy syndrome. *Pediatr Neurol* 2001;24:361-4.
3. Matthys LA, Coppage KH, Lambers DS, Barton JR, Sibai BM. Delayed postpartum preeclampsia: An experience of 151 cases. *Am J Obstet Gynecol* 2004;190:1464-6.
4. Martin J, Sidman R. Late postpartum eclampsia: a common presentation of an uncommon diagnosis. *J Emerg Med* 2003;25:387-90.
5. Ahn KJ, You WJ, Jeong SL. Atypical manifestation of reversible posterior leukencephalopathy syndrome: findings on diffusion imaging and ADC mapping. *Neuroradiology* 2004; 46:978-983.
6. Naidu K, Moodley J, Corr P, Hoffmann M. Single photon emission and cerebral computerised tomographic scan and transcranial Doppler sonographic findings in eclampsia. *Br J Obstet Gynaecol* 1997; 104:1165-1172.
7. Vaughan CJ, Delanty N. Hypertensive emergencies. *Lancet* 2000;356:411-417.

Cite this article as: Khurana M, Mahajan D, Anand M, Chhabra A. Posterior reversible encephalopathy syndrome: A rare entity. *Int J Med and Dent Sci* 2015; 4(1):658-660.

**Source of Support: Nil
Conflict of Interest: No**