

Pyogenic granuloma: A diagnostic dilemma

Vaidya S¹, Kapoor C², Ohri N³, Singh HP

¹Dr. Sharad Vaidya

M.D.S, Department of
Prosthodontics & Implantology
I.T.S. Center for Dental Studies &
Research
Muradnagar, Ghaziabad,U.P, India

²Dr. Charu Kapoor

Senior Lecturer, Department of Oral
& Maxillofacial Pathology &
Microbiology
Bhojia Dental College
Baddi, Solan, H.P, India

³Dr. Neera Ohri

MDS, Department of Oral Medicine &
Radiology
Govt. Dental College-Banglore, India

⁴Dr. Harkanwal Preet Singh

Senior Lecturer, Oral & Maxillofacial
Pathology & Microbiology
SDD-Dental College
Barwala, Panchkula, H.P, India

Received: 10-12-2012

Revised: 23-12-2012

Accepted: 30-12-2012

Correspondence to:

Dr. Charu Kapoor

9882429302

chrkapoor@gmail.com

ABSTRACT

Pyogenic granuloma (lobular capillary hemangioma) is a common acquired vascular lesion of the skin and mucous membranes in the pediatric age group. Pyogenic granuloma and hemangioma of oral cavity are well-known benign lesions. The clinical diagnosis and differentiation of these lesions is at times difficult. The purpose of this article is to report an unusual case of benign tumor occurring on hard palate which was clinically diagnosed as pyogenic granuloma and histopathologically as capillary hemangioma.

Key words: Pyogenic granuloma, capillary hemangioma

Introduction

Pyogenic Granuloma (PG) is a common tumor-like growth of the oral cavity or skin that is considered to be non-neoplastic in nature. [1, 2] Hüllihen's description [3] in 1844 was most likely the first PG reported in English literature, but the term "pyogenic granuloma" or "granuloma pyogenicum" was introduced by Hartzell in 1904. [4] Although it was originally thought to be caused by pyogenic organisms, it is now

believed to be unrelated to infection. So the term "pyogenic granuloma" was considered as a misnomer because the lesion does not contain pus and is not strictly speaking a granuloma. [2] Granuloma Pyogenicum, also called granulation tissue type haemangioma, is a lesion of uncertain neoplastic nature and is considered a polypoid form of capillary haemangioma. About 30% of these lesions develop after trauma, growing rapidly to reach a

maximum size of 2 cm within a few weeks (Schoen, 1994).^[5, 6] These lesions occur mainly in the skin but also can develop in mucosal membranes of the oral cavity and conjunctivae.^[6] Pyogenic granulomas of the oral cavity are known to involve the gingiva commonly^[4] whereas, **Hemangiomas** are benign tumors composed of blood vessels. It is subdivided into capillary hemangioma, pyogenic granuloma and cavernous hemangioma. Although World Health Organization (WHO) classification of the soft tissue tumors has been widely used, pyogenic granuloma is not listed in the classification. There have been some reports concerning about comparative study of these tumors but the detail of the lesions have been unclear. Thus the sub-classification of hemangioma is controversial. Sometimes, the histopathology of PG and capillary hemangioma presents with similar features and hence the differentiation between a capillary hemangioma and pyogenic granuloma is difficult. In fact on the basis of the histopathological picture; sometimes a PG can be called lobular capillary hemangioma.^[7,8]

Case report

A 7 year old male patient presented with a swelling on the anteriolateral part of hard palate of 1month duration. The swelling was of the size of a peanut when the parents of the patient first noticed it, but had grown rapidly over the past 1 week to

attain the present size. The growth was asymptomatic. The patient's medical history was unremarkable. Intraoral soft tissue examination revealed a solitary, pedunculated, spherical-shaped, reddish pink swelling with distinct border and irregular surface and it was located in the anterior part of lingual surface just lateral to the midline on right side in area between maxillary central incisors measuring 1.2 cm x1.8 cm in size. (Figure 1)

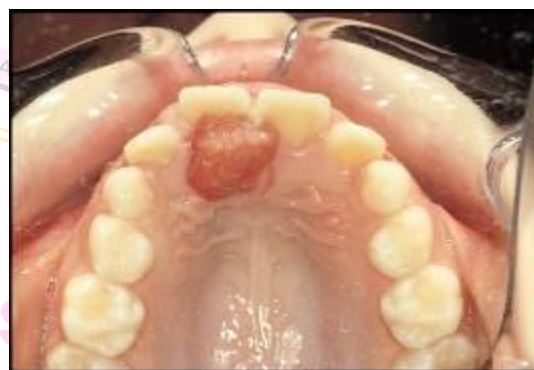

Fig. 1 Maxillary lesion showing solitary, pedunculated, reddish pink swelling on palate with distinct border and irregular surface

On palpation the swelling was non-tender, soft to firm in consistency, blanching on pressure. Intraoral hard tissue examination showed generalized stains and calculus deposition. Panoramic radiograph revealed no loss of bone in relation to the lesion. Based on its clinical signs and symptoms, a provisional diagnosis of pyogenic granuloma was established but as differential diagnosis consisted of capillary hemangioma excision under local

anesthesia with all necessary emergency equipments at hand under the guidance of a trained anesthetist was carried out. The hemogram of the patient was within normal limits except for slightly prolonged clotting time. The histopathological section of the specimen showed atrophic parakeratinized stratified squamous epithelium with large areas of ulceration. Underlying connective tissue was fibrocellular composed of numerous blood vessels lined by endothelial cells and arranged in lobular pattern separated by thin connective tissue septae. Numerous proliferating fibroblasts and budding endothelial cells were seen along with moderate amount of chronic inflammatory cell infiltrate consisting chiefly of lymphocytes. Areas of bacterial colonies with debris were also evident. Focal areas of hemorrhage were also evident. (Figure 2) Histopathological features were suggestive of capillary hemangioma with inflammatory component, secondary to ulceration.

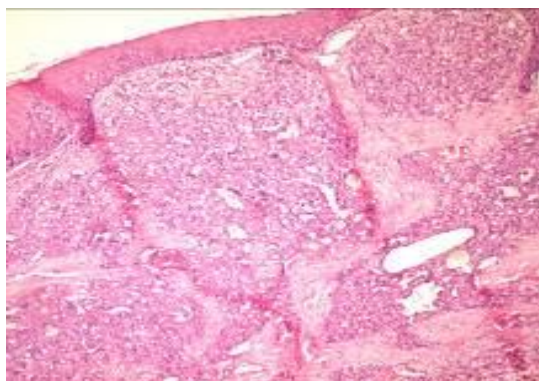


Fig. 2a

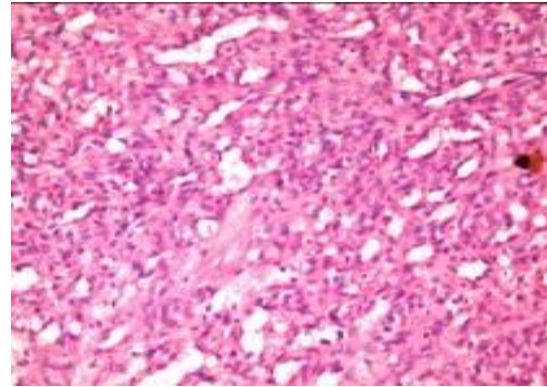


Fig. 2b 2a, 2b Showing atrophic parakeratinized stratified squamous epithelium composed of numerous blood vessels lined by endothelial cells arranged in lobular pattern separated by thin connective tissue septae.

We also reviewed the archival cases of pyogenic granuloma in our department, the demographic information, location and histopathological features. (Table 1) The clinical presentation of cases diagnosed as Pyogenic granuloma and hemangiomas was found to be similar, and many similar features were seen in the capillary (lobular) form of hemangioma as well as PG. An interesting finding was that the lobular pattern was seen only in children.

These anomalies present the necessity for sound discretion with regards to their approach therapeutically. The treatment seems to weigh heavily on individual assessments of the observer.

TABLE 1

S. No	Age/ sex	Clinical presentation	Clinical Diagnosis	Final Diagnosis
1	14/ M	Soft tissue swelling present in maxillary right posteriolateral region	Pyogenic Granuloma	Lobular Hemangioma
2	7/M	Growth in the mouth in the lower right anterior teeth region	Pyogenic Granuloma	Lobular Hemangioma

Discussion

Hemangiomas constitute 7% of all benign tumors in infancy and childhood. Hemangiomas are rare in oral cavity, though head and neck region occurrence is relatively common, representing at least a third of all hemangiomas in humans.^[3, 6] In addition, confusion with other conditions can occur since hemangiomas may mimic other lesions clinically, radiographically and in some cases histologically. In general, hemangiomas are developmental whereas vascular malformations are present at birth. Hemangiomas are most often recognized at an early age and encountered more frequently in females than males by ratio of 3:1.^[10,11] However our cases occurred in males. Vascular malformations occur in equal incidence among females and males. The hall mark of vascular malformations is proportionate growth throughout the life of the individual. Vascular malformations are localized or diffuse errors of embryonic development. These are also classified as capillary, lymphatic, venous, arterial or a combination of these depending on the clinical and histological appearance of abnormal channels.^[6, 12] Pyogenic granulomas frequently develop within portwine stained skin; this is particularly common with intraoral stains. Physicians

must distinguish these non-proliferative enlargements from the proliferating hemangiomas. Vascular anomalies of head and neck historically have confused clinicians over the years, secondary to inconsistent nomenclature. This has resulted in difficult study, improper diagnosis, and inappropriate treatment. The classification of hemangiomas is based on histological appearance, therefore histopathological assessment remains the most accurate and satisfactory means of diagnosis. Radiographs are advised to rule out bony destruction suggestive of central variety of hemangioma, malignancy or to identify a foreign body that should need to be removed with the lesion.^[13, 14]

An early pyogenic granuloma, with its epidermis intact, bears more resemblance to a tiny hemangioma. The pyogenic lesion usually has a pedunculated shape with a tiny stalk. The pathologist often designates the lesion a “capillary hemangioma, granuloma type” or “lobular capillary hemangioma.” It may be difficult to make a light microscopic differentiation between a true hemangioma of infancy and a pyogenic granuloma. However, pyogenic granuloma exhibits immunocytochemical

and ultrastructural differences. It is predominantly perithelial, rather than an endothelial tumor. Such atypical presentations, like the case in discussion can be rather confusing and can lead to erroneous diagnosis of other more serious lesion. Most small capillary hemangiomas like the one in the present case, reported in the literature, have been treated with curettage. [2] Local complications, which tend to occur in the proliferative phase, include bleeding and ulceration. Bleeding occurs when the epithelial basement membrane has been penetrated by hemangioma. This condition usually responds to local pressure or simple mattress sutures. Ulceration can lead to pain, infection, or recurrent bleeding. Central hemangiomas of jawbone or intraosseous hemangiomas and large lesions would not be a candidate for this mode of therapy. Because of rich collateral circulation in the maxilla, ligation of one or more of the major arteries may not arrest hemorrhage in the area of surgery. Such cases can be treated more conservatively with embolization and sclerosing agents. [14,15] Other treatment modalities consist of ligation and excision, artificial ulceration, electrolysis and thermocautery, sclerosant therapy, radiation and compression depending on the clinical features and the anatomic considerations. Current management consists of 'primum non nocere' ie spontaneous involution, steroid therapy and chemotherapy. [15] The lesion

was small, neither was it life threatening in nature on presentation and radiographically as it did not show any bony involvement, and therefore it did not require immediate surgical control of hemorrhage. Hence, it was decided to treat this case by simple excision under necessary precautions. [16]

The term hemangioma is used inconsistently, some sources including vascular malformations, others classifying vascular malformations separately. Furthermore, not all lesions exhibit similar clinical or histopathological characteristics. Dental surgeons should therefore be aware of these risks during diagnosis and management and should take necessary precautions prior to attempts at excision of apparently innocent lesions.

References

1. Neville BW, Damm DD, Allen CM, Bouquot. Oral & maxillofacial pathology. 2nd ed. Philadelphia: WBSaunders; 2002. p.437-95.
2. Vilmann A, Vilmann P, Vilmann H. Pyogenic granuloma: evaluation of oral conditions. Br J Oral Maxillofac Surg 1986; 24:376-82.
3. Hullihen SP. Case of aneurism by anastomosis of the superior maxillae. Am J Dent Sc 1844; 4:160-62.
4. Hartzell MB. Granuloma pyogenicum. Cutan Dis Syph 1904; 22:520-25.
5. Yao T, Nagai E, Utsunomiya T, Tsuneyoshi M. An intestinal counterpart of pyogenic granuloma of the skin. A newly proposed

- entity. Am J Surg Pathol 1995; 19:1054-60.
6. Fowler EB, Cuenin MF, Thompson SH, Kudryk VL, Billman MA. Pyogenic granuloma associated with guided tissue regeneration: a case report. J Periodontol 1996; 67:1011- 15.
 7. Schoen FJ. Vessels B. In: Kumar V, Abbas AK, Fausto N, editors. Robbins and Cotran: Pathological basis of disease. 7th ed. Philadelphia: Saunders; 2004.p.511-54.
 8. Angelopoulos AP. Pyogenic granuloma of oral cavity: Statistical analysis of it's clinical features. J Oral Surg 1971; 29:840-7.
 9. Corell RW, Wescott WB, Siegel WM. Rapidly growing, nonpainful ulcerated swelling in the posterolateral palate. J Am Dent Assoc 1983; 106:494-5.
 10. Wood NK, Goaz PW. Differential diagnosis of oral and maxillofacial lesions. 5th Ed. Missouri: Mosby; 1997.p.549-50.
 11. Kaplan I, Mass E, Littner M. A study of small superficial capillary hemangiomas on the lips in children. Pediatr Dent 1998; 20:188-91.
 12. Shenoy SS, Dinkar AD. Pyogenic granuloma associated with bone loss in an eight year old child: A case report. J Indian Soc Pedod Prev Dent 2006; 24:201-3.
 13. Shafer WG, Hine MK, Levy BM. A Textbook of Oral Pathology. 4th ed. Philadelphia: WB Saunders; 1983.p.359-60.
 14. Acikgoz A, Sakalliglu U, Ozdamar S, Uysal A. Rare benign tumours of oral cavity – capillary haemangioma of palatal mucosa: A case report. Int J Paed Dent 2000; 10:161-5.
 15. Mulliken JB. Cutaneous Vascular Anomalies. In: Mccarthy JG Editor. Plastic Surgery: Tumors of Head and Neck and Skin. Vol Philadelphia: B Saunders Company Ltd; 1990.p.3194-230.
 16. Greene LA, Freedman PD, Friedman JM, Wolf M. Capillary hemangioma of the maxilla. Oral Surg Oral Med Oral Pathol 1990; 70:268-73.

Cite this article as: Vaidya S, Kapoor C, Ohri N, Singh HP. Pyogenic Granuloma/ Lobular Hemangioma: A Diagnostic Dilemma. Int J Med and Dent Sci 2013; 2(1):88-93.

Source of Support: Nil
Conflict of Interest: No